

# Favorable surgical outcomes and perioperative complication rates after robotic radical cystectomy and intracorporeal urinary diversion at a single, low-volume center: Initial experience with 65 consecutive cases

Keita Nakane<sup>1</sup>, Torai Enomoto<sup>2</sup>, Masayuki Tomioka<sup>3</sup>, Tomoki Taniguchi<sup>4</sup>, Makoto Kawase<sup>1</sup>, Kota Kawase<sup>1</sup>, Daiki Kato<sup>1</sup>, Manabu Takai<sup>1</sup>, Koji Inuma<sup>1</sup>, Kensaku Seike<sup>4</sup>, Noriyasu Hagiwara<sup>2</sup>, Hiromi Uno<sup>4</sup>, Kazuya Yuhara<sup>3</sup> and Takuya Koie<sup>1</sup>

## Institutional affiliations

<sup>1</sup>Department of Urology, Gifu University Graduate School of Medicine, Gifu, Japan

<sup>2</sup>Department of Urology, Matsunami General Hospital, Hashima-gun, Japan

<sup>3</sup>Department of Urology, Japanese Red Cross Takayama Hospital, Takayama, Japan

<sup>4</sup>Department of Urology, Chuno Kosei Hospital, Seki, Japan

## Corresponding author

Takuya Koie,

Department of Urology, Gifu University Graduate School of Medicine, 1-1 Yanagido, Gifu 5011194, Japan.

Email: [goodwin@gifu-u.ac.jp](mailto:goodwin@gifu-u.ac.jp)

Received Date: Sep 22, 2021

Accepted Date: Sep 23, 2021

Published Date: Nov 01, 2021

## 1. Abstract

**1.1. Purpose:** This study aimed to evaluate the surgical outcomes and perioperative complications among patients who underwent robot-assisted radical cystectomy (RARC) with intracorporeal urinary diversion (ICUD).

**1.2. Methods & materials:** We retrospectively reviewed the clinical and pathological records of 65 consecutive patients who underwent RARC with ICUD between November 2018 and June 2021 at Gifu University. The patients were divided into three groups according to the type of urinary diversion: ureterocutaneostomy (UC), ileal conduit (IC), and ileal neobladder (NB). The endpoints of this study were surgical outcomes and perioperative complications according to the type of UD.

**1.3. Results:** There were no significant differences between the IC and NB groups with respect to the total operation time. Twenty-

seven complications were registered in the first 90 days. The most frequent early complication was urinary tract infection in 11 patients.

**1.4. Conclusion:** Our initial experience with RARC followed by ICUD was favorable, with acceptable surgical outcomes and perioperative complications.

**2. Key Words:** Malignant tumor of the urinary bladder, Robot-assisted radical cystectomy, Robot-assisted intracorporeal urinary diversion

## 3. Introduction

Radical cystectomy (RC) followed by urinary diversion (UD) is a definitive treatment modality for muscle-invasive bladder cancer (MIBC) and very high-risk or treatment-refractory non-invasive bladder cancer (NMIBC) [1]. Recently, minimally invasive surgical approaches, including laparoscopic RC (LRC) and robot-assisted RC (RARC), have been rapidly adopted for the treatment of MIBC, improving perioperative morbidity and the ease of recovery [2]. Although LRC cannot be widely implemented because of a prolonged learning curve and technically challenging procedure, RARC has been gradually adopted as a surgical treatment option for MIBC [3]. The RAZOR trial, a randomized open-label phase-III non-inferiority trial, demonstrated that RARC was non-inferior to open RC (ORC), based on 2-year progression-free survival rates [4]. However, all patients enrolled in the RAZOR trial underwent RC followed by extracorporeal urinary diversion (ECUD) [4].

RARC with intracorporeal UD (ICUD) may have potential advantages, including smaller incisions, reduced pain, accelerated bowel recovery, and reduced third-space fluid loss [5]. In fact, the proportion of ICUDs increased from 9% in 2005 to 97% in 2015 in 26 institutions included in the International Robotic Cystectomy Consortium (IRCC) [6]. In addition, the incidence of high-grade complications after ICUD decreased significantly with time, from 25% in 2005 to 6% in 2015 ( $P < 0.001$ ), while high-grade complications remained stable for ECUD at 13% in 2005 and 14% in 2015 ( $P = 0.76$ ) [6]. However, rates of surgical outcomes and perioperative complications may be affected by case selection,

surgeon training and experience, and high-volume institutions [5].

The aim of this study was to evaluate the surgical outcomes and perioperative complications of 65 consecutive patients who underwent RARC followed by total ICUD at a single institution in Japan.

#### 4. Materials and Methods

##### 4.1. Patients

The study protocol and informed consent documents were reviewed and approved by the Gifu University Institutional Review Board (No. 2018-154).

We retrospectively reviewed the clinical and pathological records of 170 consecutive patients with malignant tumor of the urinary bladder who underwent RC and bilateral pelvic lymphadenectomy (PLND), with or without neoadjuvant chemotherapy (NAC), between December 2004 and January 2021 at Gifu University in Japan. Our study focused on patients with malignant tumor of the urinary bladder who underwent RARC followed by ICUD. The patients were divided into three groups according to the type of urinary diversion: ureterocutaneostomy (UC), ileal conduit (IC), and ileal neobladder (NB).

##### 4.2. Treatment schedule of NAC

The NAC regimen consisted of 1000 mg/m<sup>2</sup> of gemcitabine on days 1, 8, and 15 and 70 mg/m<sup>2</sup> of cisplatin or carboplatin at an area under the curve of 5 according to Calvert's formula [7] on day 2. Each cycle lasted for 21 or 28 days. Patients who had been using anti-cancer agents before surgery received at least two cycles of NAC. The patients were identified as cisplatin-ineligible if they met at least one of the following criteria: European Cooperative Oncology Group performance status of 2, creatinine clearance <60 mL/min, hearing loss grade ≥2, neuropathy grade ≥2, and/or New York Heart Association Class III heart failure [8].

##### 4.3. Surgical procedure with RARC followed by ICUD

RARC with total ICUD was performed by four robotic surgeons. One surgeon has an experience of over 50 cases of RARC followed by ICUD at our institution and other hospitals. The new surgeon performed RARC or ICUD for the patients on the console in a step-wise manner under the supervision of an expert surgeon. Our surgical techniques for RARC have been described in detail previously [9]. The trocar for the second arm as a camera port was placed 2 cm above the umbilicus, that for the first arm on the left side was placed 9 cm away from the camera port at the umbilical level, the trocar for the fourth arm was placed 3 cm

vertically above the iliac crest on the right, and that for the third arm was placed 9 cm away from the camera port and 5 cm above the umbilical level. In addition, three assistant trocars were placed (Figure 1).

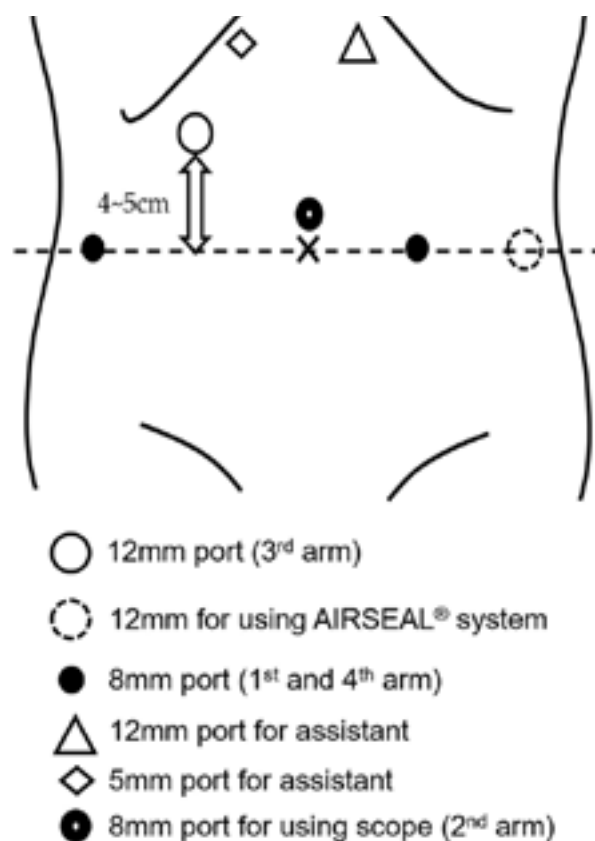


Figure 1: Port replacement

PLND, including the hypogastric, external iliac, and obturator lymph nodes, was performed

ICUD was performed using our previously reported surgical technique [10]. The Wallace surgical technique was adopted for uretero-ileal anastomosis [11]. A 12-mm port was placed at the planned level of the final IC stoma on the abdominal wall. Laparoscopic bowel-grasping forceps with two guidewires were inserted in the bowel segment through a 12 mm port, and guidewires were inserted into both the ureters.

IC NB was constructed as previously described [12]. Briefly, our U-shaped NB reconstruction replicated the open surgery procedure. The first step was to identify the most mobile ileum that reaches the urethra without tension. A 40-cm bowel segment was chosen for the neobladder. The second step was to fix the ileal segment to the pelvic floor. The ileal segment was detubularized

at the antimesenteric border using monopolar scissors. The third step was to perform urethro-ileal anastomosis. Monopolar scissors were used to create the neomeatus at the bottom of the pouch wall. Urethro-ileal anastomosis was initiated with suturing of the ileal edge to the posterior aspect of the urethral stump, starting at the 6 o'clock position, using two 15-cm 3-0 V-Loc™ sutures to inosculate the right and left sides. After suturing on both sides until the 3 or 9 o'clock position was reached, the future neobladder was hulled to the urethra. Subsequently, an 18 F urethral catheter was inserted into the future neobladder. Following which, anastomosis was continued in an anterior pattern in a running fashion, up to the 12 o'clock position. The fourth step was to perform uretero-ileal anastomosis. Here, two small enterotomies were created in the U-flap, and the ureters were introduced into the future neobladder. A 4-0 braided polyglactin suture was used to make an anastomosis with interrupted sutures. A 6-F single-J ureteric stent was placed over a guidewire inserted through the newly placed 5-mm port on the pubic bone. After ureteral anastomosis, the U-flap was cross-folded to form a pouch. The remaining anterior neobladder wall was closed using 15-cm 3-0 V-Loc™ sutures.

Bilateral intracorporeal UC was created using a retroperitoneal approach. Two small incisions were made for the stoma of UC after RARC. The peritoneum was dissected from the abdominal wall to create the retroperitoneal space. A 5-mm port was inserted directly into the retroperitoneal space. Then, the distal end of the ureter was pulled out to the body surface, and UC was performed according to Toyoda's method [13]. Finally, the peritoneal window was closed to place the ureter in the extraperitoneal position.

The choice of urinary diversion was determined according to the surgeon's and/or patient's preferences. Patients aged ≥80 years with advanced comorbidities and/or suspected carcinoma in situ (CIS) in the upper urinary tract were selected for UC.

4.4. Patient evaluation

The following baseline information was obtained from the patient's records: complete history and physical examination, Eastern Cooperative Oncology Group performance status, abdominal and pelvic CT or MRI, and chest radiography or CT.

Tumors were measured at baseline and before the RC. The diagnosis of MIBC or NMIBC was confirmed by a single pathologist at Gifu University after reviewing the results of the transurethral resection and MRI at baseline. Pathological examination of complete transmural sections of the bladder wall

was performed to accurately determine the pathological stage. All tumors were staged according to the 8th edition of the 2010 American Joint Committee on Cancer Staging Manual [14]. All perioperative complications were classified according to the Clavien-Dindo classification.<sup>15</sup>

4.5. Statistical analysis

The endpoints in this study were surgical outcomes, including operative time, estimated blood loss (EBL), and perioperative complications according to the type of UD. Data were analyzed using the software JMP 14 (SAS Institute Inc., Cary, NC, USA). Differences among the three groups were compared using Fisher's exact test or Kruskal-Wallis test for categorical variables. All p-values were two-sided, and the significance level was set at *P* < 0.05.

5. Results

5.1. Patient characteristics

The demographic data of the enrolled patients according to UD type are shown in Table 1.

Covariates	UC	IC	NB	P value
Number	19	26	20	
Age (years, median, IQR)	82 (73-85)	74 (69-77)	64 (52-69)	<0.001
Gender (number, %)				
Male	12 (63.2)	19 (73.1)	17 (85.0)	<0.001
Female	7 (36.8)	7 (26.9)	3 (15.0)	
ASA score (number, %)				
1	1 (5.3)	4 (15.4)	6 (30.0)	0.041
2	16 (74.2)	22 (84.6)	14 (70.0)	
3	2 (10.5)	0	0	
Clinical T (number, %)				
T1±	4 (21.1)	1 (3.8)	2 (10.0)	0.630
T1	0	2 (7.7)	1 (5.0)	
T2	6 (31.6)	14 (53.9)	6 (30.0)	
T3	7 (36.8)	5 (19.2)	10 (50.0)	
T4±	2 (10.5)	4 (15.4)	1 (5.0)	
Clinical N (number, %)				
Negative	17 (89.5)	22 (84.6)	20 (100)	0.198
positive	2 (10.5)	4 (15.4)	0	
NAC (number, %)	9 (61.5)	20 (76.9)	17 (88.0)	0.050
Follow-up period (months, median, IQR)	10.7 (3.0-12.6)	14.4 (7.4-22.6)	13.9 (7.9-18.3)	0.018

Table 1: Clinical characteristics of patients

UC: ureterocutaneostomy, IC: ileal conduit, NB: ileal neobladder, IQR: interquartile range, ASA: the American Society of Anesthesiologists

A total of 65 patients were treated with RARC followed by ICUD between November 2018 and June 2021 at our institution. None of the patients underwent ORC or LRC during the same period. The median age of the patients was 72 years (interquartile range [IQR], 66–78 years), and the median follow-up period was 12.6 months (IQR, 6.4–18.1 months). According to age, the patients in the UC group were significantly older than those in other groups. The UC group was composed of eleven patients aged  $\geq 80$  years, four patients diagnosed with CIS, two patients with American Society of Anesthesiologists physical status 3, and two patients who underwent radical nephrectomy before RARC. Ten patients did not receive NAC because of advanced age ( $\geq 85$  years;  $n = 6$ ), CIS ( $n = 3$ ), adenocarcinoma ( $n = 1$ ). With regard to the follow-up period, the patients in the UC group were significantly shorter than those in other groups.

Variables	UC	IC	NB	P value
Number	19	26	20	
Console time for total procedure (minutes, median, IQR)	151 (153-203)	337 (317-366)	409 (376-445)	<0.001
Operation time for UD (minutes, median, IQR)	27 (25-30)	104 (91-125)	181 (159-245)	<0.001
Estimated blood loss (mL, median IQR)	115 (20-240)	210 (118-304)	402 (112-500)	0.004
Pathological stage (number, %)				
pT0	2 (10.5)	6 (23.1)	5 (20.0)	0.791
pT1a	1 (5.3)	3 (11.5)	1 (5.0)	
pT1	3 (15.8)	4 (15.4)	1 (5.0)	
pT2	4 (21.1)	5 (19.2)	5 (20.0)	
pT3	7 (31.5)	4 (15.4)	6 (30.0)	
pT4	3 (15.8)	4 (15.4)	2 (10.0)	
Histopathological diagnosis				
Urothelial carcinoma	18 (94.7)	25 (96.2)	16 (87.4)	0.124
Squamous cell carcinoma	1 (5.3)	0	1 (5.0)	
Adenocarcinoma	0	1 (3.8)	1 (5.0)	
Small cell carcinoma	0	0	1 (5.0)	
Leiomyosarcoma	0	0	1 (5.0)	
Lymph node involvement (number, %)	1 (5.3)	2 (7.7)	2 (10.0)	0.358
Positive surgical margin (number, %)	0	0	1 (5.0)	0.341
Time to fluid intake (days, median, IQR)	1 (1-1)	1 (1-1)	1 (1-1)	>0.999
Time to dietary intake (days, median, IQR)	2 (2-2)	3 (2-3)	3 (3-3)	<0.001
Length of hospital stay (days, median, IQR)	19 (17-25)	23 (21-27)	25 (22-28)	0.010

Table 2: Surgical and perioperative outcomes.

UC: ureterocutaneostomy, IC: ileal conduit, NB: ileal neobladder, IQR: interquartile range, UD: urinary diversion

RARC with ICUD was successfully completed in all patients without open conversion. The median operation time for RARC was 119 minutes (IQR, 102–141 min). The median number of lymph nodes resected was 10. The time from the isolation of the

small bowel segment to the side-to-side anastomosis of the small intestine was 34 min. Although the operation was not shorter in UC cases, there were no significant differences between the IC and NB groups with respect to the total operation time. One patient diagnosed with pathological T4 stage disease in the NB group had a positive surgical margin. None of the patients with LN involvement or positive surgical margins underwent adjuvant therapies, including chemo-therapy or radiation.

At the end of the follow-up period, 10 patients experienced recurrence and 4 died of BC. The metastatic sites were local recurrence in 3 patients, liver and bone in 2 patients, and urethra, leptomeningeal metastasis, and peritonitis carcinomatosa in 1 patient, respectively.

### 5.3. Perioperative complications

A total of 27 complications were registered in the first 90 days after surgery. The most frequent early complication was urinary tract infection (26.9%) in 11 patients. The other total complications were postoperative ileus in 8 patients (12.3%), ileo-urethral anastomotic stricture in 4 patients (6.2%), and surgical site infection in 4 patients (6.2%). Of these, grade 3 complications occurred in five patients-ureteral stenosis in four patients (two patients each in the IC and NB groups), lymphocele in one patient in the UC group, and rectal injury in one patient in the IC group. None of the patients died within 90 days of surgery.

### 6. Discussion

Although the number of patients who underwent RARC has dramatically increased in the past decade, the process of adoption of ICUD by surgeons remains slow. ICUD is still considered a challenging procedure because of technical difficulties, longer operative time, and steep learning curve [16,17]. In fact, performing an ICUD remains to be a challenging part of surgical practice, especially the manipulation of the small intestine, for many urologists. Several postoperative complications are associated with ICUD [16]. Although recent studies have reported that there were no significant differences in 90-day high-grade complication rates between ORC and RARC [4,18], ICUD may require prolonged operative time and have potential disadvantages with early perioperative complications; therefore, ECUD should be preferred [19]. From the IRCC database, ICUD is associated with increased rates of complications compared to ECUD (57% vs. 43%,  $P < 0.001$ ) [6]. However, the incidence of high-grade complications after ICUD significantly decreased from 25% in 2005 to 6% in 2015 ( $P < 0.001$ ), while it remained stable for ECUD at 13% in



2005 and 14% in 2015 ( $P = 0.76$ ) [6]. In particular, the readmission rate in patients who underwent ECUD was significantly higher than that in patients who underwent ICUD ( $P = 0.003$ ) [6]. To date, ICUD may have several advantages in terms of perioperative complications after surgery.

Filson et al. reported several important factors related to operative time: potential modifiable operative factors, including PLND; the type of UD; surgical technique; and non-modifiable factors, including patient age and sex, and the experiences of surgeons and institutions [20]. In fact, the adoption of ICUD has a steep learning curve, with continued improvements in perioperative outcomes beyond 40 cases [21]. On the other hand, a high annual RARC was associated with lesser operative time.<sup>6</sup> In addition, higher experience and flattening of the learning curve may lead to a decreased operative time [6]. For these reasons, high-volume centers have improved outcomes by introducing a step-by-step standardized technique [20]. In addition, this may reflect the clustering of high-volume surgeons to high-volume hospitals or streamlining of the intraoperative pathway to optimize performance [22]. Although our institution is not a high-volume hospital, the surgical outcomes were relatively favorable and acceptable compared with other high-volume hospitals [5,6,16,21]. However, one (1.9%) patient developed peritonitis carcinomatosa 3 months after surgery. The patient was initially diagnosed with clinical T3bN1M0 MIBC and received two courses of neoadjuvant gemcitabine and carboplatin because of a 24-h creatinine clearance 49.7 mL/min. After NAC, the patient showed stable disease according to the Response Evaluation Criteria in Solid Tumors, version 1.1 [22]. Pathological findings revealed pathological T4a high-grade urothelial carcinoma. In addition, the patient had lymphovascular invasion, despite no lymph node involvement and negative surgical margins. Thus, we believe that pneumoperitoneum may affect tumor cell seeding, leading to peritonitis carcinomatosa.

Other perioperative outcomes associated with the quality of surgery, including EBL, blood transfusion rate, and length of hospital stay (LOS), have been widely adopted in RARC [3]. Randomized controlled trials (RCTs), assessing the quality of surgical outcomes between RARC and ORC, revealed that RARC leads to substantially fewer blood transfusions (193 transfusions per 1,000 RARC patients and 460 transfusions per 1,000 ORC patients) [23]. Sathianathan et al. reported a similar reduction in blood transfusion rates by 42% in the RARC group compared to the ORC group [16]. In the RAZOR trial, EBL in the RARC group

was significantly lower than that in the ORC group ( $P < 0.001$ ), and RARC patients required less frequent intraoperative (13.6% vs. 33.6%;  $P = 0.0002$ ) and postoperative blood transfusions (25.6% vs. 41.0%;  $P = 0.0089$ ) [4]. This may be the result of improved visualization and the tamponade effect of the pneumoperitoneum [24].

The current study has several limitations. First, this was a retrospective study with an inherent potential for bias. Second, a relatively small number of patients were enrolled in this study, with a relatively short follow-up period. Therefore, a longer period of careful observation of oncological and functional consequences is necessary.

## 7. Conclusions

RARC with ICUD is a minimally invasive surgery performed in patients who undergo RC. Indeed, the application of RARC and ICUD have dramatically increased in the last decade. However, in the current situation, selective referral to high-volume surgeons or institutions may secure a positive quality of care, including shorter operative time and lower perioperative complication rates, for patients undergoing RARC. In this study, our initial experience with RARC followed by ICUD was favorable, with acceptable surgical outcomes and perioperative complications. Based on our experience, low referral centers may provide better surgical outcomes with RARC followed by ICUD, if surgeons have abundant experience and sufficient surgical technique with RC. It is necessary to standardize the operation procedure for BC using the RARC and ICUD.

**Authors' contributions:** All authors contributed to the study conception and design. Material preparation, data collection and analysis were performed by Keita Nakane, Torai Enomoto, Masayuki Tomioka, Tomoki Taniguchi, Makoto Kawase, Kota Kawase, Daiki Kato, Manabu Takai, Koji Iinuma and Kensaku Seike. Statistical analysis was done by Keita Nakane. Supervision was Noriyasu Hagiwara, Hiromi Uno and Kazuya Yuhara. The first draft of the manuscript was written by Keita Nakane and Takuya Koie, and all authors commented on previous versions of the manuscript. All authors read and approved the final manuscript.

**Ethics approval:** Ethics Review Committee Institution of Gifu University Institutional Review Board (No. 2018-154).

## References

1. Muscle-invasive and Metastatic Bladder Cancer. The European Association of Urology. 2021. <https://uroweb.org/guideline/bladder-cancer-muscle-invasive-and-metastatic/>
2. Khan MS, Gan C, Ahmed K, Ismail AF, Watkins J, Summers JA, et al. A single-centre early phase randomised controlled three-arm trial of open, robotic, and laparoscopic radical cystectomy (CORAL). *Eur Urol*. 2016;69(4):613-21.
3. Brodie A, Kijvikai K, Decaestecker K and Vasdev N. Review of the evidence for robotic-assisted robotic cystectomy and intra-corporeal urinary diversion in bladder cancer. *Trans Androl Urol*. 2020;9(6):2946-55.
4. Parekh DJ, Reis IM, Castle EP, Gonzalgo ML, Woods ME, Svatek RS, et al. Robot-assisted radical cystectomy versus open radical cystectomy in patients with bladder cancer (RAZOR): an open-label, randomised, phase 3, non-inferiority trial. *Lancet*. 2018;391(10139):2525-36.
5. Hussein AA, Elsayed AS, Aldhaam NA, Jing Z, Peabody JO, Wijburg CJ, et al. A comparative propensity score-matched analysis of perioperative outcomes of intracorporeal vs extracorporeal urinary diversion after robot-assisted radical cystectomy: results from the International Robotic Cystectomy Consortium. *BJU Int*. 2020;126(2):265-72.
6. Hussein AA, May PR, Jing Z, Ahmed YE, Wijburg CJ, Canda AE, et al. Outcomes of intracorporeal urinary diversion after robot-assisted radical cystectomy: results from the International Robotic Cystectomy Consortium. *J Urol*. 2018;199(5):1302-11.
7. Calvert AH, Newell DR, Gumbrell LA, O'Reilly S, Burnell M, Boxall FE, et al. Carboplatin dosage: prospective evaluation of a simple formula based on renal function. *J Clin Oncol*. 1989;7(11):1748-56.
8. Galsky MD, Hahn NM, Rosenberg J, Sonpavde G, Hutson T, Oh WK, et al. Treatment of patients with metastatic urothelial cancer "unfit" for cisplatin-based chemotherapy. *J Clin Oncol*. 2011;29(17):2432-8.
9. Koie T, Ohyama C, Yamamoto H, Imai A, Hatakeyama S, Yoneyama T, et al. The feasibility and effectiveness of robot-assisted radical cystectomy after neoadjuvant chemotherapy in patients with muscle-invasive bladder cancer. *Jpn J Clin Oncol*. 2017;47(3):252-6.
10. Nakane K, Muramatsu Maekawa Y, Iinuma K, Mizutani K, Makiyama K and Koie T. Utility technique of a totally intracorporeal ileal conduit after robot-assisted radical cystectomy. *Int J Urol*. 2019;26(11):1083-4.
11. Wallace DM. Ureteric diversion using a conduit: a simplified technique. *Br J Urol*. 1966;38(5):522-7.
12. Koie T, Ohyama C, Yoneyama T, Nagasaka H, Yamamoto H, Imai A, et al. Robotic cross-folded U-configuration intracorporeal ileal neobladder for muscle-invasive bladder cancer: Initial experience and functional outcomes. *Int J Med Robot*. 2018;14(6):e1955.
13. Toyoda Y. A new technique for catheterless cutaneous ureterostomy. *J Urol*. 1977;117(3):276-8.
14. Paner GP, Stadler WM, Hansel DE, Montironi R, Lin DW and Amin MB. Updates in the eighth edition of the Tumor-Node-Metastasis staging classification for urologic cancers. *Eur Urol*. 2018;73(4):560-9.
15. Clavien PA, Barkun J, de Oliveira ML, Vauthey JN, Dindo D, Schulick RD, et al. The Clavien-Dindo classification of surgical complications. *Ann Surg*. 2009;250(2):187-96.
16. Hosseini A, Mortezaei A, Sjöberg S, Laurin O, Adding C, Collins J, et al. Robot-assisted intracorporeal orthotopic bladder substitution after radical cystectomy: perioperative morbidity and oncological outcomes - a single-institution experience. *BJU Int*. 2020;126(4):464-71.
17. Tanneru K, Jazayeri SB, Kumar J, Alam MU, Norez D, Nguyen S, et al. Intracorporeal versus extracorporeal urinary diversion following robot-assisted radical cystectomy: a meta-analysis, cumulative analysis, and systematic review. *J Robot Surg*. 2020;15(3):321-33.
18. Sathianathan NJ, Kalapara A, Frydenberg M, Lawrentschuk N, Weight CJ, Parekh D, et al. Robotic assisted radical cystectomy vs open radical cystectomy: systematic review and meta-analysis. *J Urol*. 2019;201(4):715-20.
19. Balbay MD, Koc E and Canda AE. Robot-assisted radical cystectomy: patient selection and special considerations. *Robot Surg*. 2017;4:101-6.
20. Filson CP, Tan HJ, Chamie K, Laviana AA and Hu JC. Determinants of radical cystectomy operative time. *Urol Oncol*. 2016;34(10):431.e17-24.
21. Collins JW, Tyrirtis S, Nyberg T, Schumacher MC, Laurin O, Adding C, et al. Robot-assisted radical cystectomy (RARC) with intracorporeal neobladder - what is the effect of the learning curve on outcomes? *BJU Int*. 2014;113(1):100-7.
22. Eisenhauer EA, Therasse P, Bogaerts J, Schwartz LH, Sargent D, Ford R, et al. New response evaluation criteria in solid tumours: revised RECIST guideline (version 1.1). *Eur J Cancer*. 2009;45(2):228-47.
23. Rai BP, Bondad J, Vasdev N, Adshead J, Lane T, Ahmed K, et al. Robotic versus open radical cystectomy for bladder cancer in adults. *Cochrane Database Syst Rev*. 2019;4(4):CD011903.
24. Lobo N, Thurairaja R, Nair R, Dasgupta P and Khan MS. Robot-assisted radical cystectomy with intracorporeal urinary diversion - The new 'gold standard'? Evidence from a systematic review. *Arab J Urol*. 2018;16(3):307-13.